Original Article
Neonatal Med 2017 May;24(2):83-87
https://doi.org/10.5385/nm.2017.24.2.83
pISSN 2287-9412 . eISSN 2287-9803

neonatal medicine

Can Treatment of Patent Ductus Arteriosus with Ibuprofen Compared to Supportive Management Affect Regional Brain Volume in Very Low Birth Weight Infants? A Pilot Study

Jae Hoe Koo, M.D., Keum Nho Lee, M.D., Hyug-Gi Kim, M.D.*, Kyung Mi Lee, M.D*, and Yong-Sung Choi, M.D.
Departments of Pediatrics and Radiology*, Kyung Hee University School of Medicine, Seoul, Korea

ABSTRACT

Purpose: This study aimed to compare cerebral hemispheric volumes between pharmacologic treatment and supportive management of patent ductus arteriosus (PDA).

Methods: The study was conducted retrospectively. The subjects of period 1 group were very low birth weight infants whose PDA were treated with pharmacologic closure. Period 2 group were treated with supportive management. Regional brain volumes measured using magnetic resonance imaging were compared between the two groups.

Results: A total of 12 infants were included. Their median gestational age was 27^{+6} (range: 24^{+1}–31^{+1}) weeks and birth weight was 1,065 g (range: 690–1,380). Between the two groups, there was no difference in Apgar score, incidence of bronchopulmonary dysplasia, necrotizing enterocolitis, and culture proven sepsis. The regional brain volumes such as gray matter (Period 1 group, 76,833 mm^3 [55,759–100,388] vs. Period 2 group, 79,870 mm^3 [59,957–113,018], P=0.59), white matter (82,993 mm^3 [63,130–121,311] vs. 92,576 mm^3 [77,200–104,506], P=0.18), cerebrospinal fluid (17,167 mm^3 [9,279–22,760] vs. 14,348 mm^3 [7,018–27,604], P=0.94), basal ganglia (2,065 mm^3 [1,697–2,482] vs. 2,306 mm^3 [2,065–3,009], P=0.18), and cerebellum (18,374 mm^3 [14,843–24,657] vs. 18,096 mm^3 [16,134–23,627], P=0.94) were not different between the two groups.

Conclusion: Regional brain volumes were not different between pharmacological and conservative treatment in infants with PDA. Further well controlled studies are required to evaluate the advantages or disadvantages of supportive management without pharmacologic treatment of PDA.

Key Words: Patent ductus arteriosus, Preterm infants

Received: 14 July 2016
Revised: 25 October 2016
Accepted: 11 May 2017
Correspondence to: Yong-Sung Choi
Department of Pediatrics, Kyung Hee University School of medicine, Kyungheedae-ro 23, Dongdaemoon-gu, Seoul 02447, Korea
Tel: +82-958-2921
Fax: +82-958-8113
E-mail: feelhope@khu.ac.kr

Copyright(c)
By Korean Society of Neonatology.
All right reserved.
This is an Open-Access article distributed under the terms of the Creative Commons Attribution Non-Commercial License (http://creativecommons.org/licenses/by-nc/4.0), which permits unrestricted non-commercial use, distribution, and reproduction in any medium, provided the original work is properly cited.

INTRODUCTION

Hemodynamically significant patent ductus arteriosus (PDA) is a common problem in the first week after birth in preterm infants, especially in infants with gestational age, GA <28 weeks[1-3]. PDA in preterm infants in the postnatal period is associated with an increased risk of bronchopulmonary dysplasia[1,2], prolonged mechanical ventilation[4], necrotizing enterocolitis (NEC), intraventricular hemorrhage (IVH), periventricular leukomalacia (PVL), cerebral palsy, and increase in mortality[5-7]. The current management of PDA in preterm infants includes pharmacologic closure, surgical ductal ligation, or supportive management for spontaneous closure[8]. However, there are no randomized controlled trials comparing the 3 different approaches, and there is an ongoing debate regarding the ideal treatment of PDA in preterm infants[9]. Because the rate of spontaneous ductus closure in infants weighing <1,000 g is very high, 35% by 6 days after birth, 67% by 7 days after birth, and 94% before hospital discharge, hemodynamically insignificant patent ductus arteriosus seldom requires treatment[10,11]. Therefore, the treatment guidelines should be based on the clinical manifestations of hemodynamically significant PDA and tolerance in preterm infants, rather than focusing on the PDA itself. Recently, supportive approach has become more common, and pharmacologic and surgical treatments are less commonly used[9,12], but evidence supporting the treatment approaches is insufficient and the risks are not clear[9,10,13]. The brains of preterm infants achieve rapid growth during the premature period after birth, and are more vulnerable to various stresses[14,15]; therefore, PDA still remains a risk factor for PVL, IVH, and white matter damage. In particular, the decreased volume of brain tissue in preterm infants at term-equivalent age remains a concern as it can result in adverse neurodevelopmental outcomes later[16].

In this regard, the authors hypothesized that there may be certain association between decreased cerebral volume and supportive management of PDA resulting in delayed wait-and-see strategy rather than active pharmacologic treatment.

MATERIALS AND METHODS

1. Study population

This retrospective study was conducted in a single center, the neonatal intensive care unit, Department of Pediatrics, Kyung Hee University Hospital, South Korea. The subjects of this study were neonates with birth weight <1,500 g who were born between March 1, 2013 and February 29, 2016. Inclusion criteria were birth weight <1,500 g and echocardiographic evidence of PDA. Cases of surgical ligation, congenital anomaly, failure to undergo magnetic resonance imaging (MRI) at term-equivalent age were excluded. Among subjects with MRI data, those who did not undergo 3-dimensional MR imaging protocol and those with PVL, which can affect the brain parenchymal volume, were also excluded.

2. Data collection

Maternal obstetric data were collected from medical records, and neonatal data were collected by retrospective review of records. The diagnosis of PDA was based on clinical symptoms and confirmed by echocardiography. Clinical signs and symptoms included continuous heart murmur, increased heart rate, bounding pulses, widened pulse pressure, and inability to wean off of mechanical ventilation. Echocardiographic criteria for symptomatic PDA was more than 1:1.4 of left atrium : aorta with significant left to right shunt. Collected data included sex, prenatal glucocorticoid use, mode of delivery, gestational age, birth weight, Apgar score (1-min, 5-min), head circumference at birth, bronchopulmonary dysplasia (BPD), number of days of mechanical ventilation, culture-positive sepsis, and presence or absence of NEC.

3. Strategy of PDA treatment

Infants diagnosed with PDA from March 1, 2013 to December 31, 2014 were treated with either pharmacologic closure and/or surgical ligation based on an aggressive strategy (Period 1), and infants diagnosed with PDA between January 1, 2015 and February 29, 2016 received supportive care based on a supportive strategy to promote spontaneous closure (Period 2). Supportive care includes fluid restriction, diuretics use, increasing end-expiratory pressure, and oxygen use.

4. Image acquisition

MR images were acquired in each subject using a 3T MR system (Achieva, Philips Medical Systems, Best, The Netherlands) equipped with an 8-channel sensitivity encoding (SENSE) head coil. The axial structural 3-dimensional T1-weighted (T1W) spin-echo MR image was acquired to evaluate the volume of brain

Neonatal Med 2017 May;24(2):83-87
https://doi.org/10.5385/nm.2017.24.2.83

tissue with the following imaging parameters: repetition time (TR)=450 ms, echo time (TE)=10 ms, field of view (FOV)=144×160 mm^2, and voxel size=0.42×0.42×4.00 mm^3.

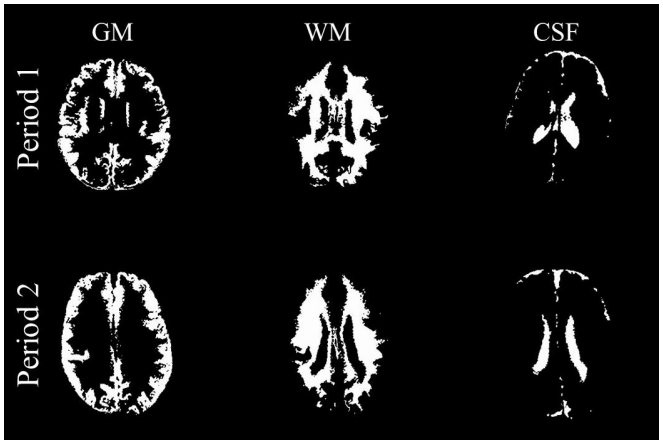

Figure 1. Segmented brain probability maps on intracranial tissues of Period 1 and Period 2 groups. The segmentation method was performed in 2D T1 WI using the new segment tool in SPM8. Abbreviations: CSF, cerebrospinal fluid; GM, cortical gray matter; WM, white matter.

5. Image analysis

The following post-processing steps were performed using a Statistical Parametric Mapping Version 8 (SPM8) program (Wellcome Department of Imaging Neuroscience, University College, London, UK). All 2-dimensional T1WIs were then segmented into gray matter (GM), white matter (WM), and cerebrospinal fluid (CSF), basal ganglia (BG), cerebellum using the new segment tool in SPM8. The total and regional brain volume was estimated with these segmented images. The brain probability maps of each voxel that contained GM, WM, CSF, BG, and cerebellum on a scale of 0 to 1 were produced from the segmented 2DT1W images. In order to focus on susceptibility changes of the brain tissues, only the voxels that contained greater than 70 percent GM, WM, CSF, BG, and cerebellum were selected to minimize the partial volume effect (Figure 1).

6. Statistical analysis

Continuous data are presented as the median (range). The two groups of infants were compared using Mann-Whitney *U* test for continuous variables and Fisher's exact test or the chi-squared

Table 1. Clinical Charateristics of the Studied Patient Groups

	Period 1 (n=6)	Period 2 (n=6)	*P*-value
Gender, male, n (%)	1 (17)	3 (50)	0.18
Gestational age (wks)	27^{+6} (24^{+1}–30^{+3})	28^{+1} (26^{+6}–31^{+1})	0.39
Birth weight (g)	1,022 (690-1,380)	1,118 (960–1,310)	0.39
Head circumference (cm)	25.3 (22-27)	24.9 (24–29)	0.94
PMA when MRI (wks)	37^{+2} (36^{+3}–39^{+0})	37^{+2} (34^{+5}–37^{+5})	0.70
Body weight when MRI (g)	2378 (1,890–2,590)	2,238 (1,904–2,445)	0.82
Head circumference when MRI (cm)	31 (29–33)	30.6 (28–34.5)	0.82
Antenatal steroid, n (%)	3 (50)	5 (83)	0.55
Delivery by cesarean section, n (%)	5 (83)	5 (83)	>0.99
Apgar score			
1 min	4 (1–7)	5.5 (3–6)	0.30
5 min	5 (3–7)	7 (5–8)	0.61
Days of ventilation (D)	32 (5–77)	19.5 (3–35)	0.57
BPD, n (%)	4 (67)	0 (0)	0.06
NEC, n (%)	2 (33)	0 (0)	0.46
Sepsis, n (%)	3 (50)	1 (17)	0.55
IVHn			
0	4	3	
1	0	3	
2	1	0	
3	1	0	

Data are presented as median (range) for continuous data and n (%) for dichotomous data.
Abbreviations: PMA, post menstrual age; BPD, bronchopulmonary dysplasia; NEC, necrotizing enterocolitis; IVH, intraventricular hemorrhage.

Table 2. MRI–Mmeasured Volumes of Brain Regions

	Period 1 (n=6)	Period 2 (n=6)	*P*-value
Gray Matter	76,833 (55,759–100,388)	79,870 (59,957–113,018)	0.59
White Matter	82,993 (63,130–121,311)	92,576 (77,200–104,506)	0.18
Cerebrospinal Fluid	17,167 (9,279–22,760)	14,348 (7,018–27,604)	0.94
Basal Ganglia	2,065 (1,967–2,482)	2,306 (2,065–3,009)	0.18
Cerebellum	18,374 (14,843–24,657)	18,096 (16,134–23,627)	0.94

Data are presented as median (range) for continuous data.

test for categorical variables. In all analyses, a *P*-value<0.05 was considered significant. Statistical analysis was performed using SPSS version 22.0 (IBM Co., Armonk, NY, USA).

RESULTS

Nine infants underwent pharmacologic treatment of PDA (Period 1 group) and 7 received supportive management (Period 2 group). Four cases of PVL were excluded in the final analysis (Period 1 group, n=3; Period 2 group, n=1). A total of 12 infants were included in this study. The 2 groups were similar in baseline characteristics, including sex, gestational age, birth weight, head circumference, antenatal steroid use, mode of delivery, 1-min and 5-min Apgar scores, NEC, and culture positive sepsis (Table 1).

Table 2 shows the summary of the volumes of the 5 regions of the brain measured by MRI. There was no significant difference in the volumes of gray matter (Period 1 group, 76,833 mm^3 [55,759–100,388] vs. Period 2 group, 79,870 mm^3 [59,957–113,018], *P*=0.59), white matter (82,993 mm^3 [63,130–121,311] vs. 92,576 mm^3 [77,200–104,506], *P*=0.18), cerebrospinal fluid (17,167 mm^3 [9,279–22,760] vs. 14,348 mm^3 [7,018–27,604], *P*=0.94), basal ganglia (2,065 mm^3 [1,697–2,482] vs. 2,306 mm^3 [2,065–3,009], *P*=0.18), and cerebellum (18,374 mm^3 [14,843–24,657] vs. 18,096 mm^3 [16,134–23,627], *P*=0.94).

DISCUSSION

Although white matter volumes between both groups were not different in our study, there are some researchers who have mentioned the possible compromised outcome due to the use of prostaglandin inhibitors. Evidence for this hypothesis was first suggested in a study in baboons by Pickard et al. in 1973, which demonstrated that cerebral blood flow was decreased when indomethacin was used[17]. A study by Wennmalm et al. in 1981 also found the same results when indomethacin was administered in adults[18], and a study of neonates by Evans et al. in 1987 also reported the same findings[19]. In contrast, a larger-scale study by Romagnoli et al. in 2000 reported no significant reduction in cerebral blood flow in neonates treated with ibuprofen[20]. However, one recent study in 2012 also stressed the adverse effect on the volume of white matter and transient reduction in cerebral flow with ibuprofen administration[21].

Our report was the first attempt to compare brain volumes at term-equivalent age between the group receiving ibuprofen treatment for PDA and the group receiving supportive management, by using volumetric 3-dimensional MRI techniques. The result was that there was no difference between ibuprofen usage group and the group receiving supportive therapy. However, it is not clear if we can make such a conclusion, because the sample size was too small. Many factors that can affect the outcome of the study were not controlled and it is a retrospective study that has profound limitations in inclusion and exclusion criteria. Nonetheless, through this study we still question the outcomes of a previous study, if ibuprofen could influence the cerebral blood flow and affect neurologic development. Therefore, further well-controlled studies are needed to evaluate the advantages or disadvantages of ibuprofen usage in the treatment of preterm infants with PDA.

REFERENCES

1) Northway WH, Jr., Rosan RC, Porter DY. Pulmonary disease following respirator therapy of hyaline-membrane disease. Bronchopulmonary dysplasia. N Engl J Med 1967;276:357-68.
2) Clyman RI. The role of patent ductus arteriosus and its treatments in the development of bronchopulmonary dysplasia. Semin Perinatol 2013;37:102-7.

3) Kim TH, Choi MS, Chung SH, Choi YS. Morbidity of low birth weight infants in Korea(2012): a comparison with Japan and the USA. Neonatal Med 2015;22:198-204.
4) Siassi B, Emmanouilides GC, Cleveland RJ, Hirose F. Patent ductus arteriosus complicating prolonged assisted ventilation in respiratory distress syndrome. J Pediatr 1969;74:11-9.
5) Gregory GA, Kitterman JA, Phibbs RH, Tooley WH, Hamilton WK. Treatment of the idiopathic respiratory-distress syndrome with continuous positive airway pressure. N Engl J Med 1971; 284:1333-40.
6) Noori S, McCoy M, Friedlich P, Bright B, Gottipati V, Seri I, et al. Failure of ductus arteriosus closure is associated with increased mortality in preterm infants. Pediatrics 2009;123:e138-44.
7) Benitz WE. Treatment of persistent patent ductus arteriosus in preterm infants: time to accept the null hypothesis? J Perinatol 2010;30:241-52.
8) Gersony WM, Peckham GJ, Ellison RC, Miettinen OS, Nadas AS. Effects of indomethacin in premature infants with patent ductus arteriosus: results of a national collaborative study. J Pediatr 1983;102:895-906.
9) Benitz WE. Learning to live with patency of the ductus arteriosus in preterm infants. J Perinatol 2011;31 Suppl 1:S42-8.
10) Nemerofsky SL, Parravicini E, Bateman D, Kleinman C, Polin RA, Lorenz JM. The ductus arteriosus rarely requires treatment in infants > 1000 grams. Am J Perinatol 2008;25:661-6.
11) Clyman RI, Couto J, Murphy GM. Patent ductus arteriosus: are current neonatal treatment options better or worse than no treatment at all? Semin Perinatol 2012;36:123-9.
12) Lemmers PM, Benders MJ, D'Ascenzo R, Zethof J, Alderliesten T, Kersbergen KJ, et al. Patent Ductus Arteriosus and Brain Volume. Pediatrics 2016;137. doi: 10.1542/peds.2015-3090.
13) Kaempf JW, Wu YX, Kaempf AJ, Kaempf AM, Wang L, Grunkemeier G. What happens when the patent ductus arteriosus is treated less aggressively in very low birth weight infants? J Perinatol 2012;32:344-8.
14) Inder TE, Warfield SK, Wang H, Huppi PS, Volpe JJ. Abnormal cerebral structure is present at term in premature infants. Pediatrics 2005;115:286-94.
15) Boardman JP, Counsell SJ, Rueckert D, Kapellou O, Bhatia KK, Aljabar P, et al. Abnormal deep grey matter development following preterm birth detected using deformation-based morphometry. Neuroimage 2006;32:70-8.
16) Keunen K, Isgum I, van Kooij BJ, Anbeek P, van Haastert IC, Koopman-Esseboom C, et al. Brain volumes at term-equivalent age in preterm infants: imaging biomarkers for neurodevelopmental outcome through early school age. J Pediatr 2016; 172:88-95.
17) Pickard JD, Mackenzie ET. Inhibition of prostaglandin synthesis and the response of baboon cerebral circulation to carbon dioxide. Nat New Biol 1973;245:187-8.
18) Wennmalm Å, Eriksson S, Wahren J. Effect of indomethacin on basal and carbon dioxide stimulated cerebral blood flow in man. Clin Physiol 1981;1:227-34.
19) Evans DH, Levene MI, Archer LN. The effect of indomethacin on cerebral blood-flow velocity in premature infants. Dev Med Child Neurol 1987;29:776-82.
20) Romagnoli C, De Carolis MP, Papacci P, Polimeni V, Luciano R, Piersigilli F, et al. Effects of prophylactic ibuprofen on cerebral and renal hemodynamics in very preterm neonates. Clin Pharmacol Ther 2000;67:676-83.
21) Bhatt M, Petrova A, Mehta R. Does treatment of patent ductus arteriosus with cyclooxygenase inhibitors affect neonatal regional tissue oxygenation? Pediatr Cardiol 2012;33:1307-14.